SISTEMA GENITAL MASCULINO

Atlas Digital

Anatomia Patológica

UFPR

UNIVERSIDADE FEDERAL DO PARANÁ
Departamento de Patologia Médica
Disciplina de Anatomia Patológica

Coordenação da Produção

Lilian Pereira Ferrari

Rafaela Pires Erthal Michelato

Elaboração do Material

Geórgia Pereira Freitas

Revisão

Samya Hamad Mehanna

É proibida a reprodução total ou parcial do trabalho sem autorização dos autores e da Universidade

Curitiba

2025

ÍNDICE

Hiperplasia Prostática 3

Hiperplasia Prostática e Adenocarcinoma Gleason 3.....4

Adenocarcinoma Prostático 6

Seminoma 8

Seminoma 10

Carcinoma Embrionário de Testículo 12

Teratoma Testicular com três folhetos 14

Ginecomastia 16

M1- HIPERPLASIA PROSTÁTICA

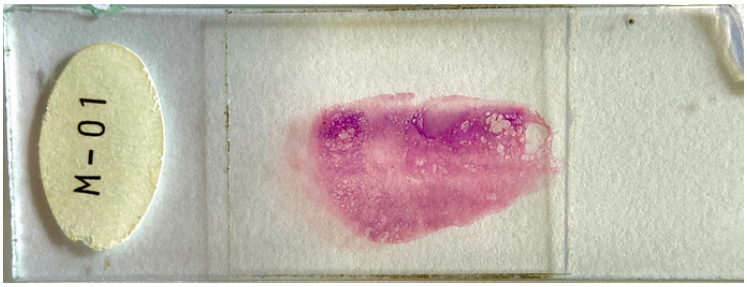

Aumento 40x:

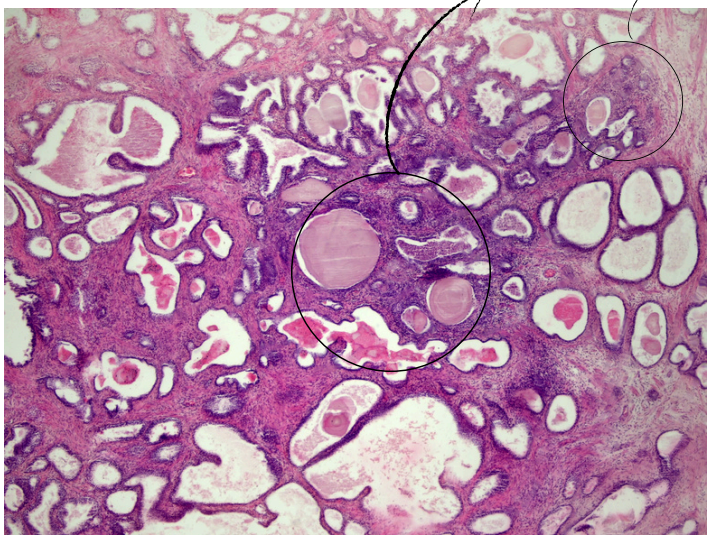

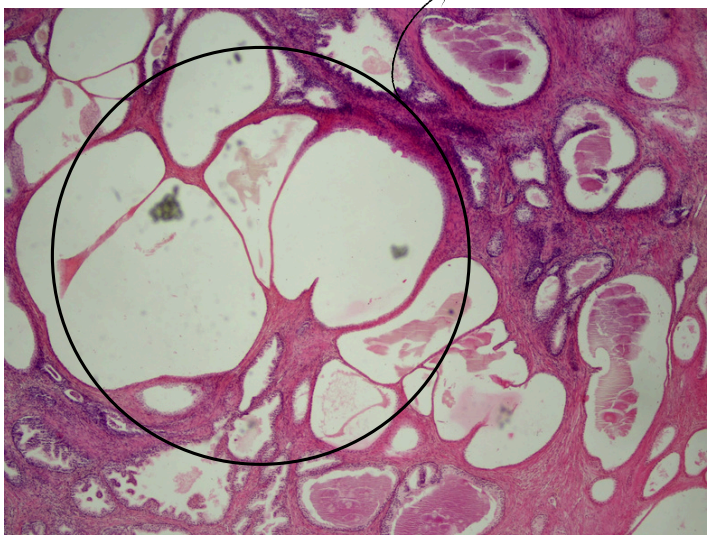

Aumento 200x:

Aumento 400x:

SAIBA MAIS...

Proliferação de glândulas de arquitetura irregulares e luzes dilatadas contendo corpos amiláceos. O epitélio é biestratificado, com células basais achatadas e luminais colunares. O estroma apresenta aumento de tecido conjuntivo e muscular liso, frequentemente com leve infiltrado linfocitário, sem sinais de atipia ou invasão. O citoplasma pálido dilatação glandular e cistificação (invaginações internas à luz dessas dilatações) caracterizando hiperplasia.

GM3- HIPERPLASIA PROSTÁTICA E ADENOCARCINOMA GLEASON 3

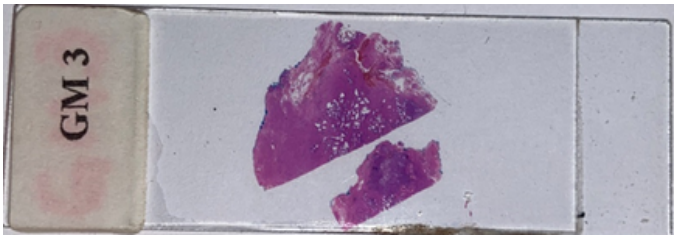

Aumento 40x:

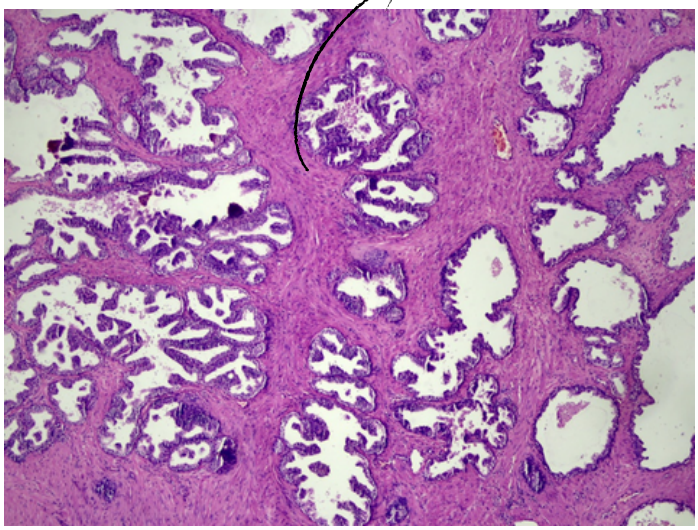

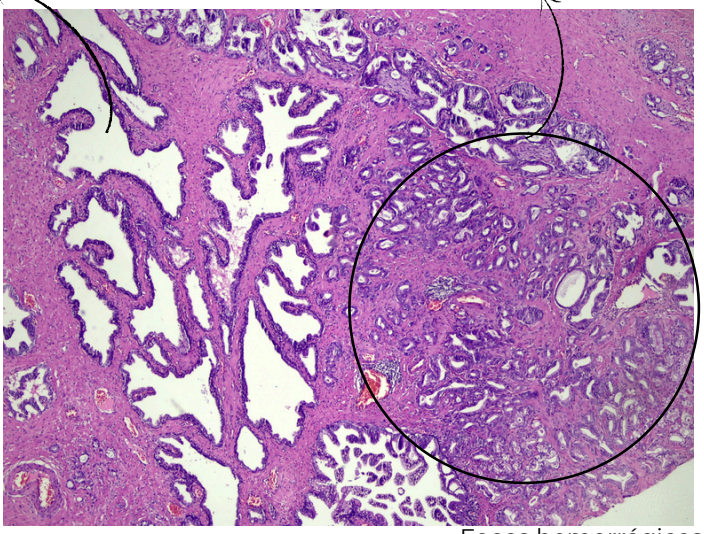

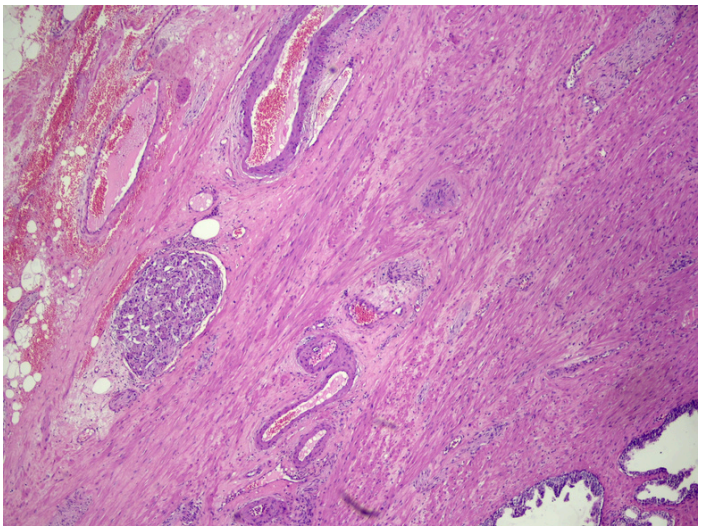

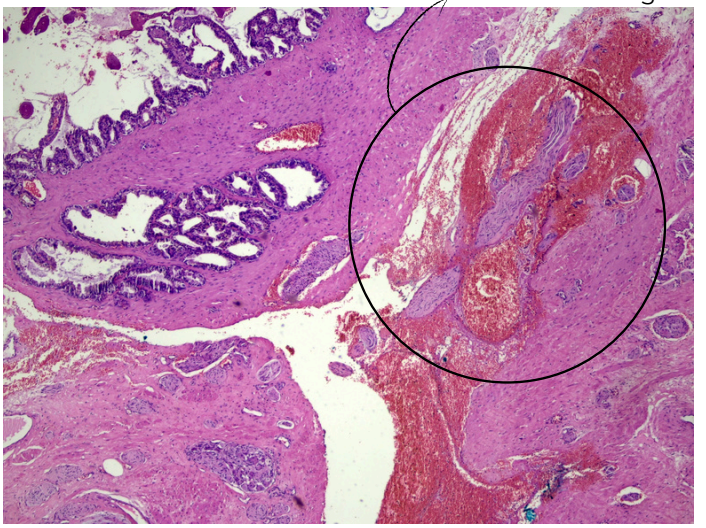

Aumento 200x:

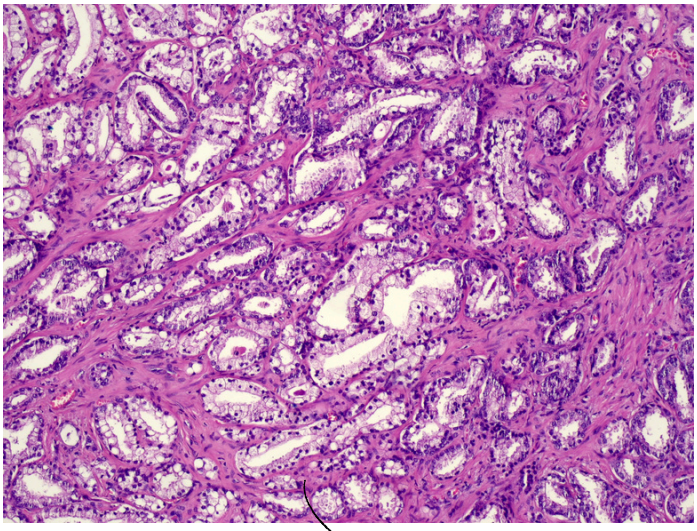

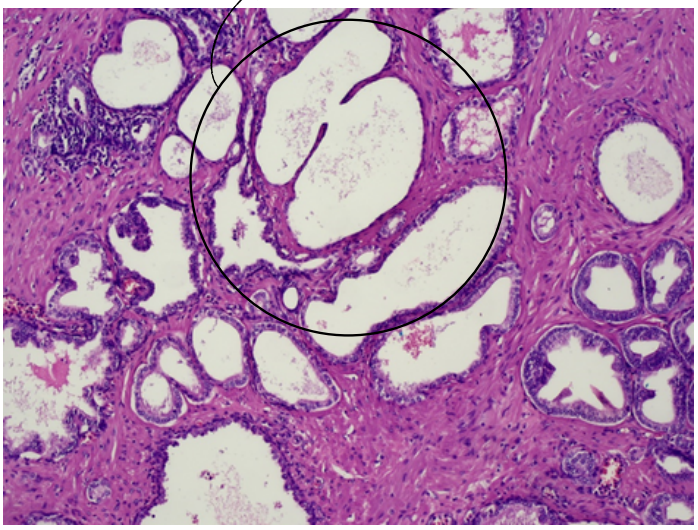

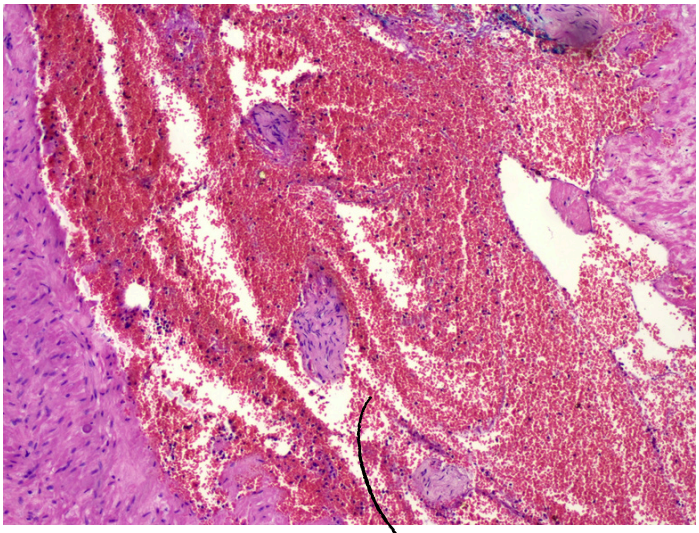

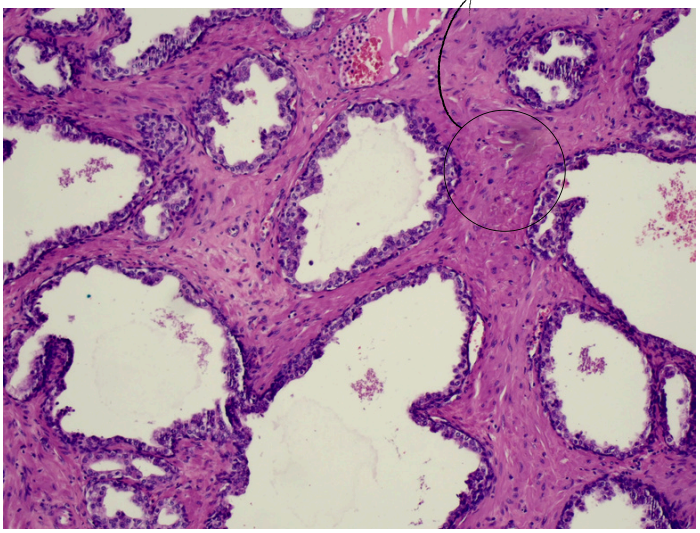

Aumento 400x:

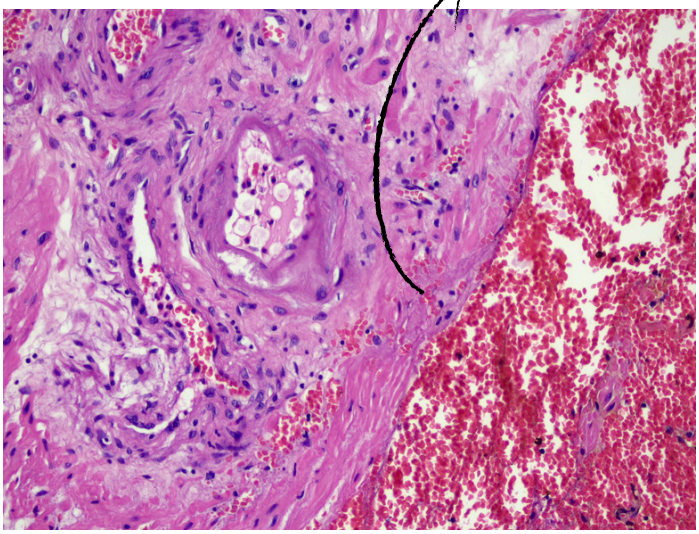

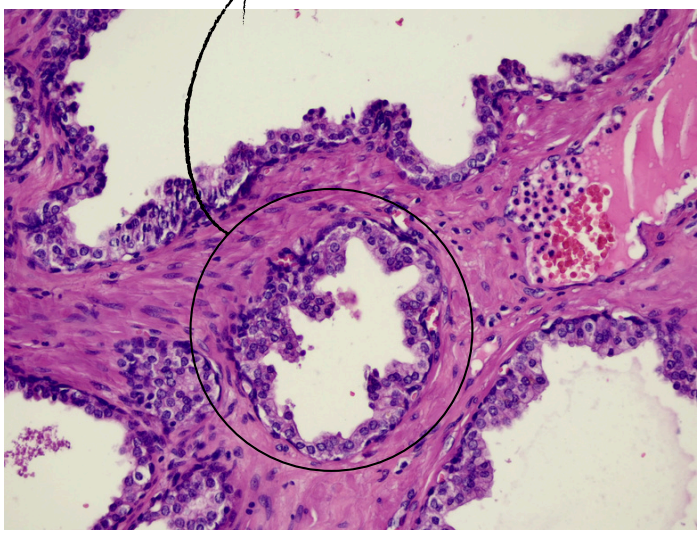

SAIBA MAIS...

Tecido fibromuscular entremeando as glândulas prostáticas. Normalmente há dupla população de células: células basais e células glandulares acima. Há, nas lâminas, dois achados: glândulas pequenas e fusionadas com nucléolos evidentes, sem dupla população de células (sendo um critério para adenocarcinoma de próstata), citoplasma pálido dilatação glandular e cistificação (invaginações internas à luz dessas dilatações) caracterizando hiperplasia.

M2- ADENOCARCINOMA PROSTÁTICO

Aumento 40x:

Dilatação = área de hiperplasia

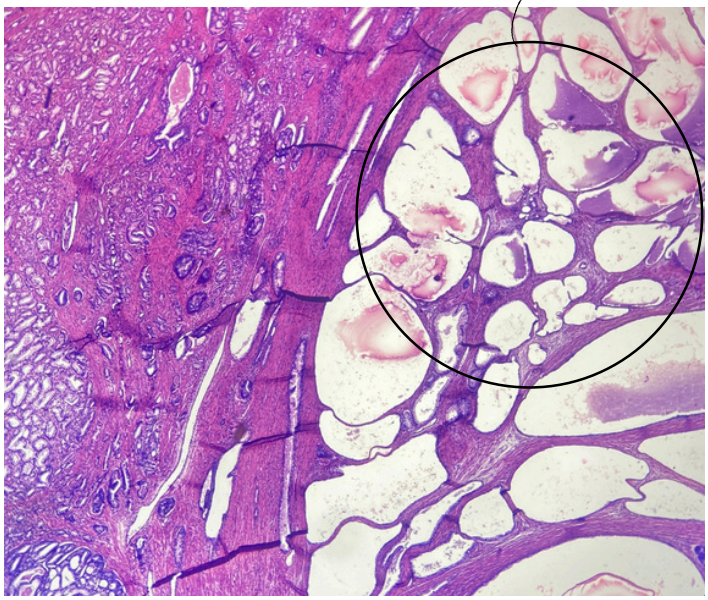

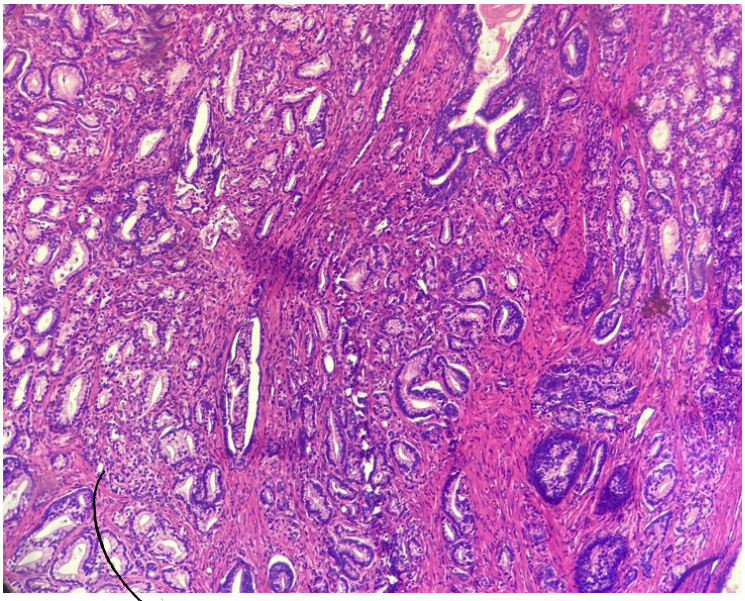

Ácinos proliferados, agrupados,
com arquitetura irregular

Aumento 100x:

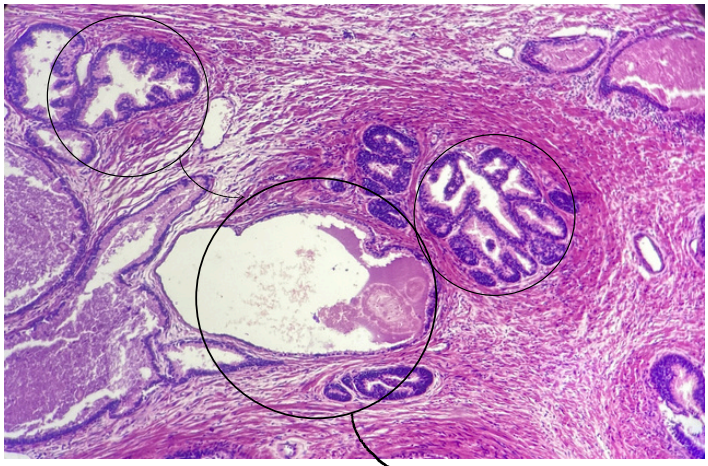

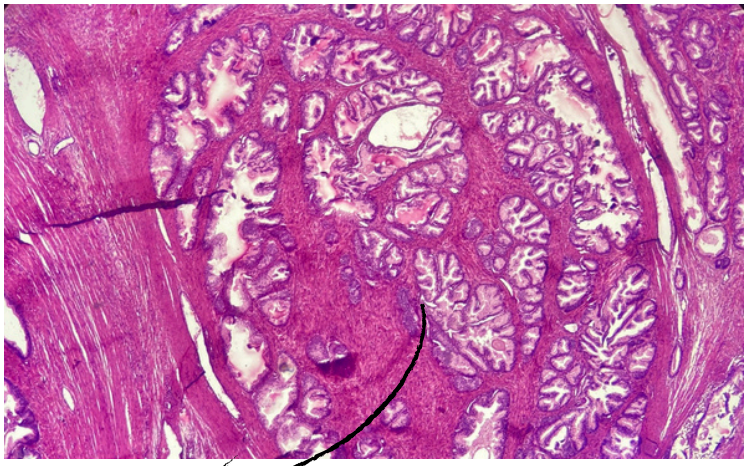

Hiperplasia nodular

Sem celulas basais
Mitoses atípicas

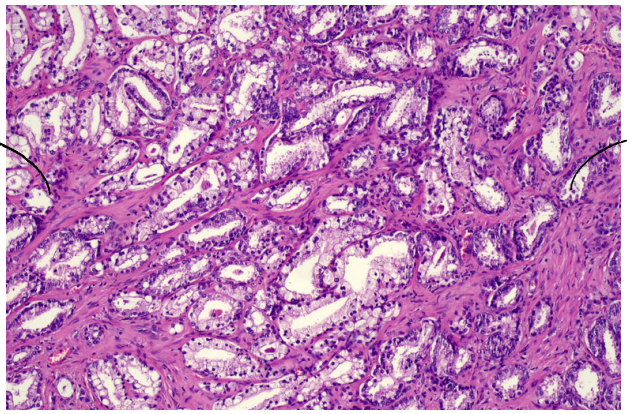

Glândulas proliferadas com
alterações arquitetônicas ->
adenocarcinoma

Aumento 200x:

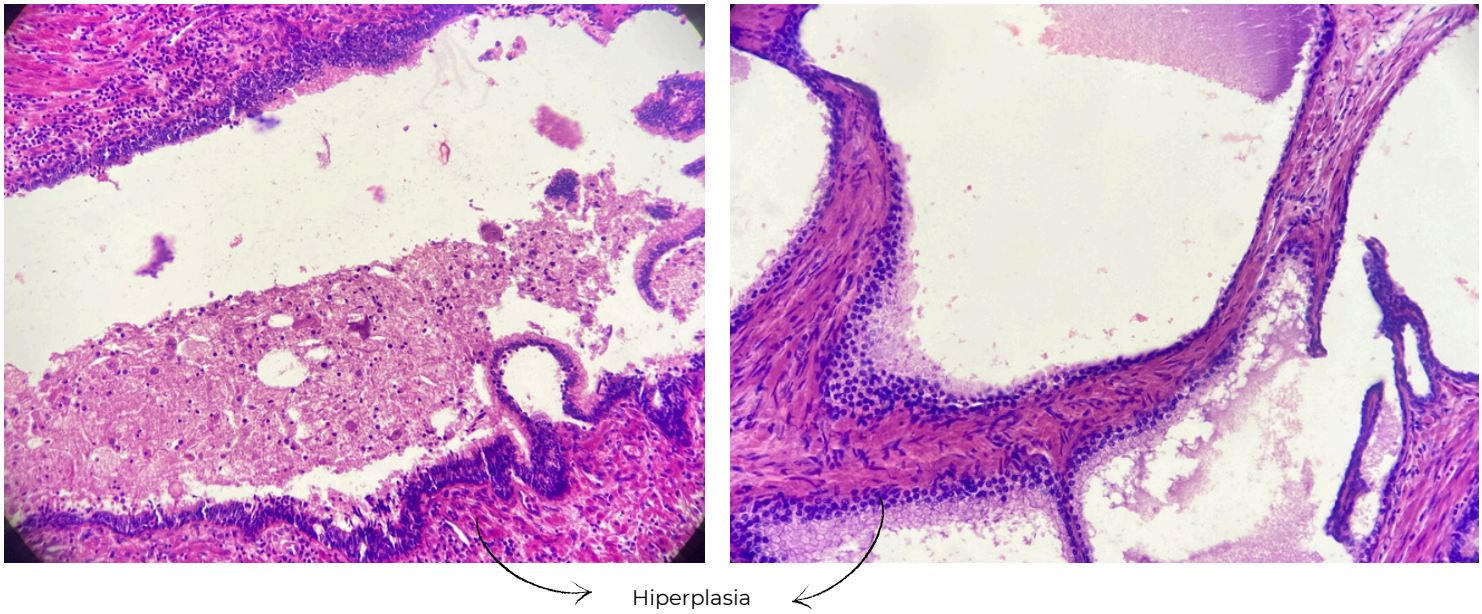

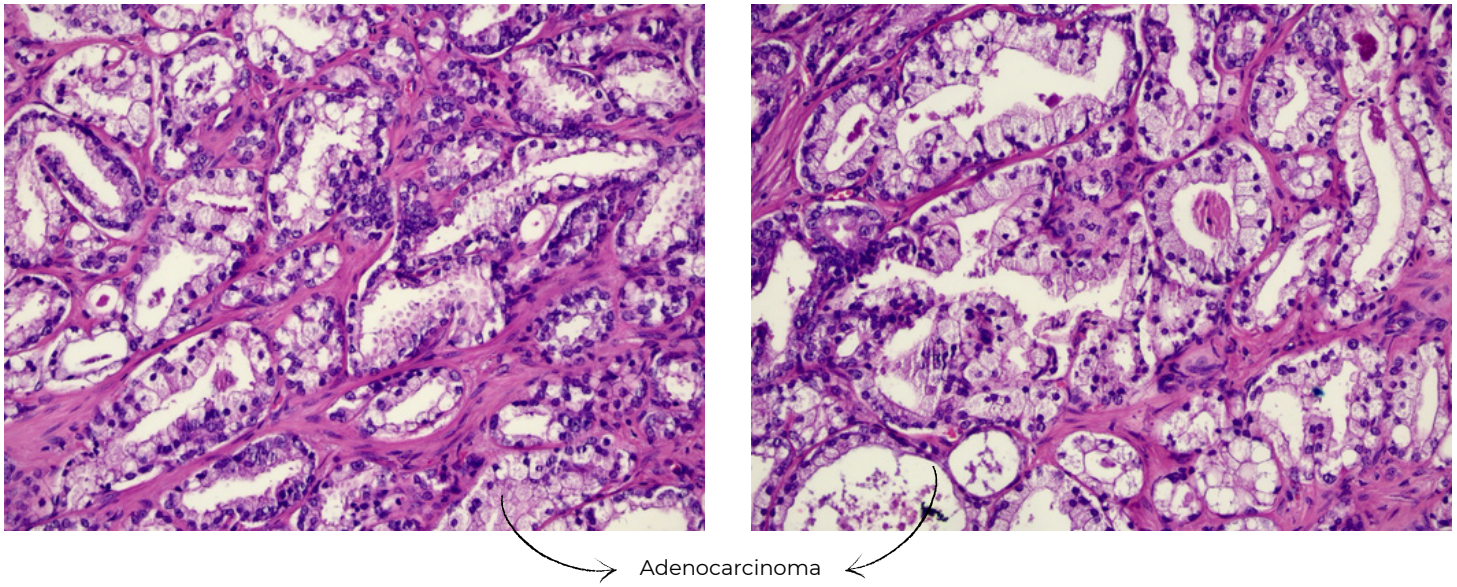

SAIBA MAIS...

Dois achados: área de hiperplasia com dilatação glandular e e ao redor de glândulas malignas, frequentemente causando distorção considerável de sua forma, agrupadas em pequenos ácidos, ausência de camada de células basais e presença de nucléolos evidentes. O sistema de Gleason é uma classificação que avalia a agressividade do câncer de próstata e é uma ferramenta importante para determinar o tratamento mais adequado para o paciente, sendo baseado em cinco padrões histológicos que determinam o nível de diferenciação tumoral (1 a 5). O escore de Gleason final é a soma dos dois padrões arquiteturais mais prevalentes observados na amostra tumoral, e pode variar de 2 a 10.

GM1- SEMINOMA (PURO)



Aumento 100x:

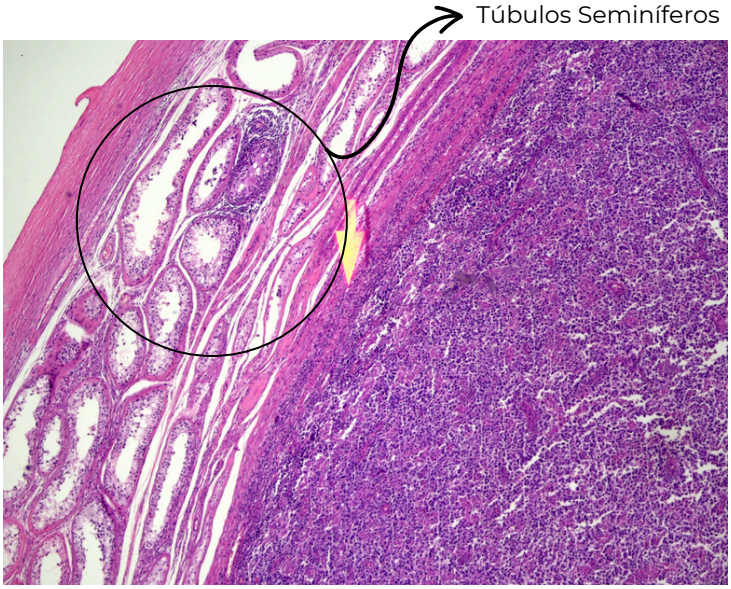

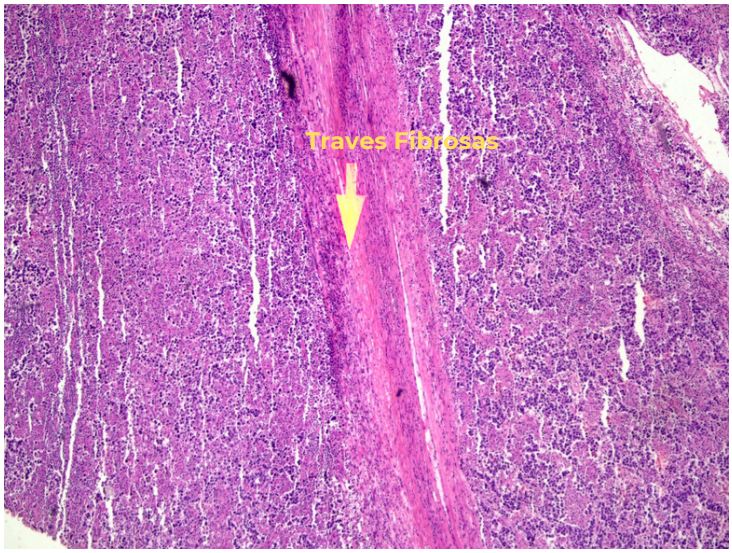

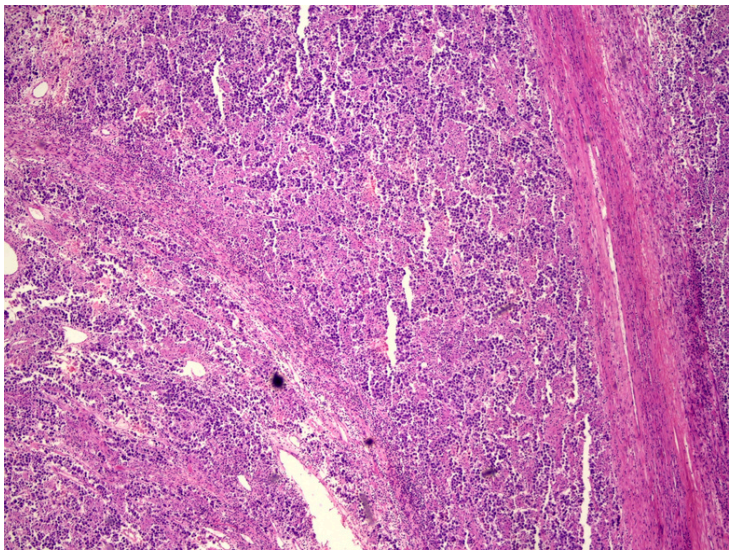

Microscopia óptica, Hematoxilina-eosina

Traves fibrosas contendo infiltrado linfocitário delimitando células tumorais

Aumento 400x:

Traves Fibrosas

Células tumorais + linfócitos

SAIBA MAIS...

O Seminoma é tumor maligno mais frequente do testículo e consiste em proliferação de túbulos seminíferos delimitando por traves fibrosas com presença de infiltrado linfocitário. Necrose e mitoses atípicas podem ser observadas. O tratamento de escolha é orquiectomia. É recomendável realizar imunoistoquímica (OCT 3/4, CD117) para a confirmação do diagnóstico e pesquisa de outros componentes germinativos associados.

M5- SEMINOMA

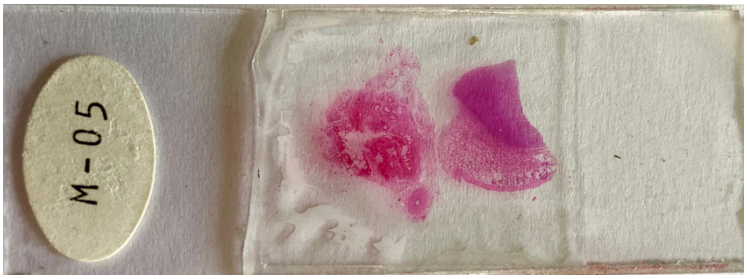

Aumento 40x:

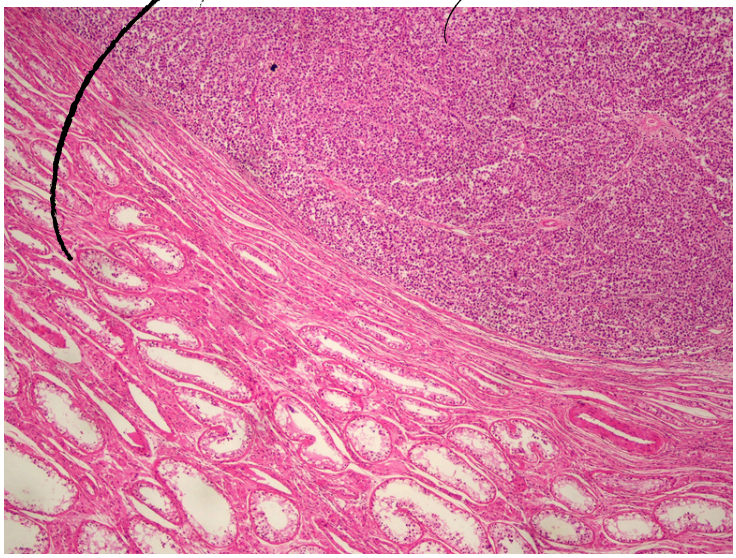

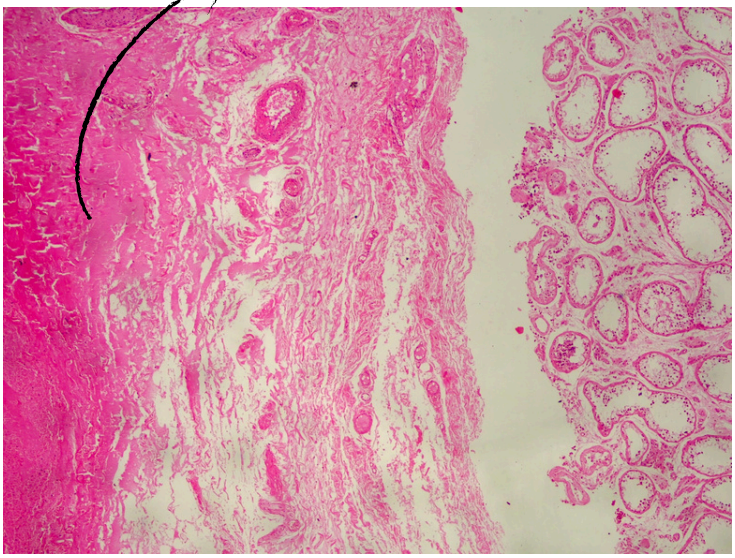

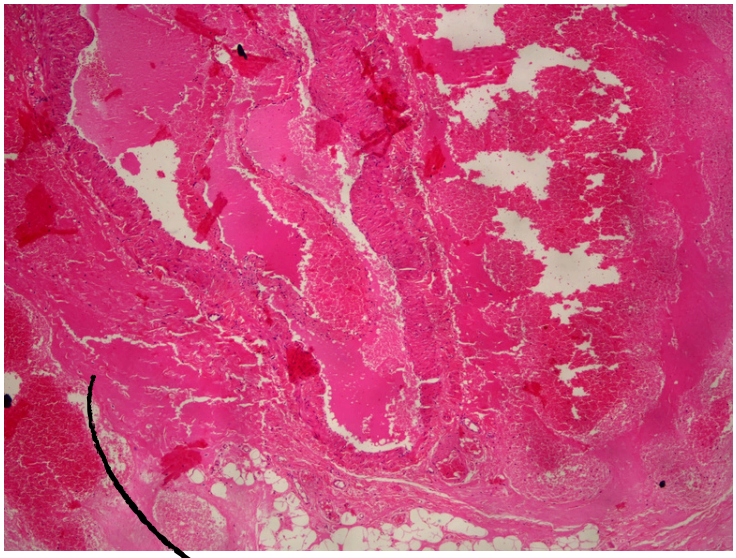

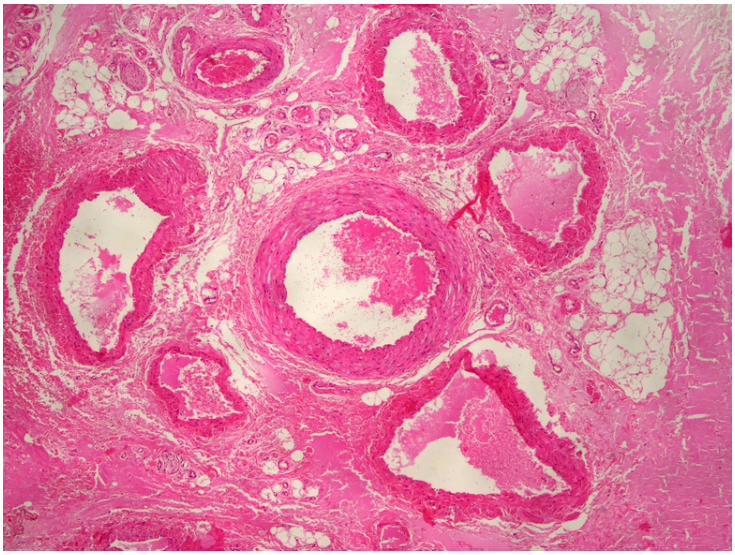

Aumento 200x:

Tubulos seminiferos peritumorais

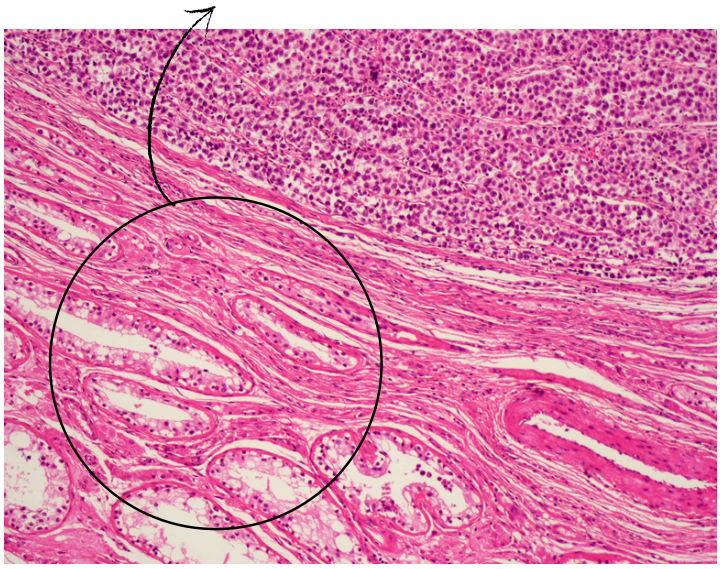

Células tumorais grandes e relativamente uniformes

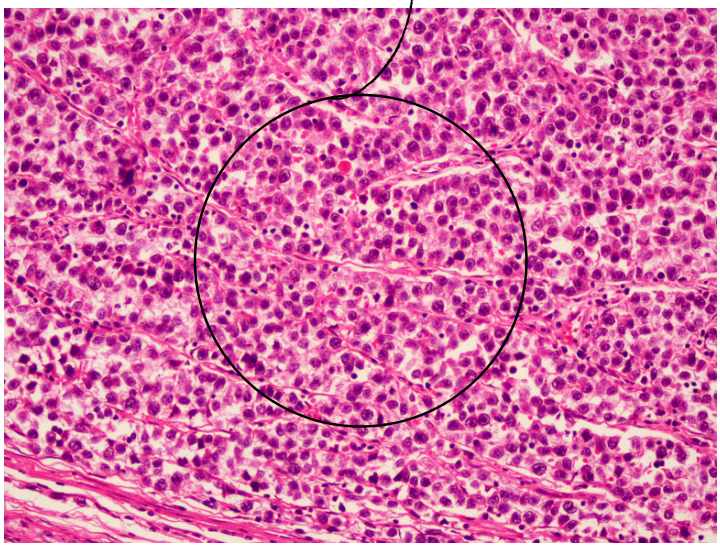

Aumento 400x:

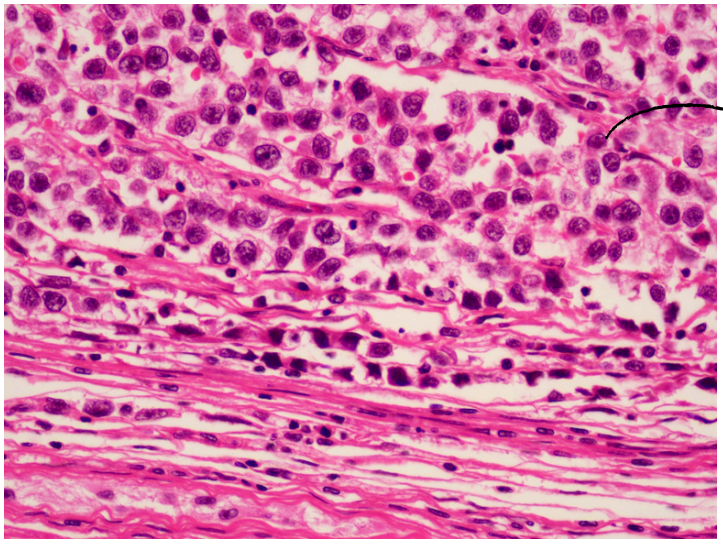

As células tumorais têm núcleos grandes, redondos, com cromatina solta e nucléolos visíveis e arranjo em ninhos.

SAIBA MAIS...

É o tumor maligno mais comum do testículo, formado por células grandes, arredondadas, arranjadas em lóbulos. Esses agrupamentos são separados por traves de estroma conjuntivo onde frequentemente se observa infiltrado inflamatório crônico do tipo linfocitário. As células neoplásicas são uniformes, com núcleos volumosos, cromatina frouxa, nucléolo evidente e citoplasma escasso e claro.

GM2- CARCINOMA EMBRIONÁRIO DE TESTÍCULO

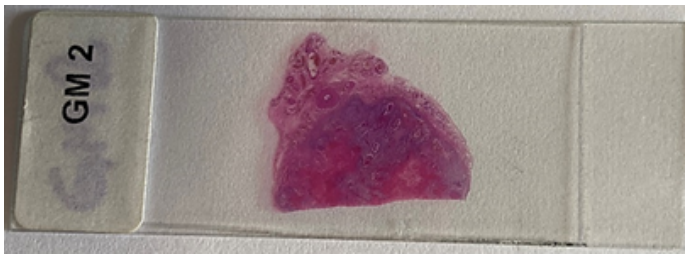

Aumento 40x:

Células tumorais agrupadas + focos hemorrágicos

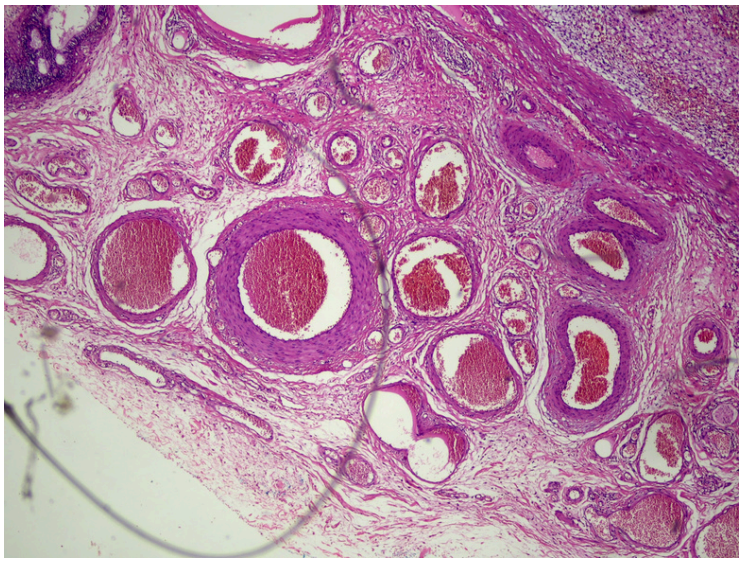

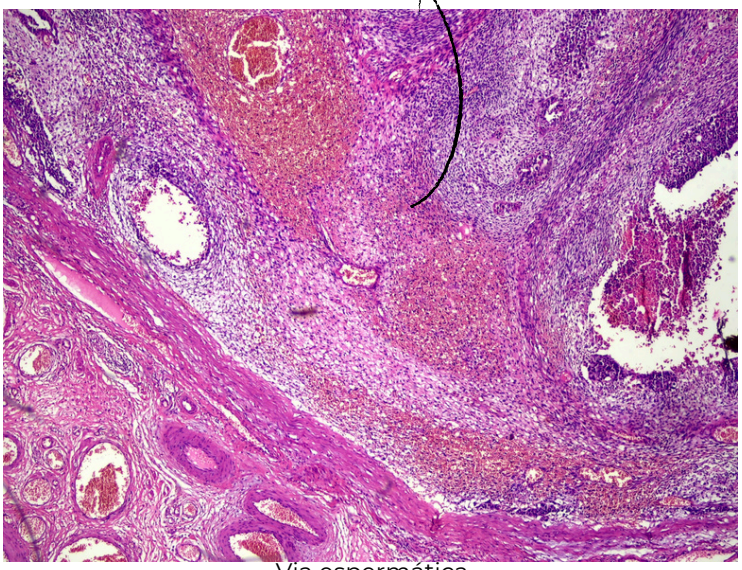

Via espermática

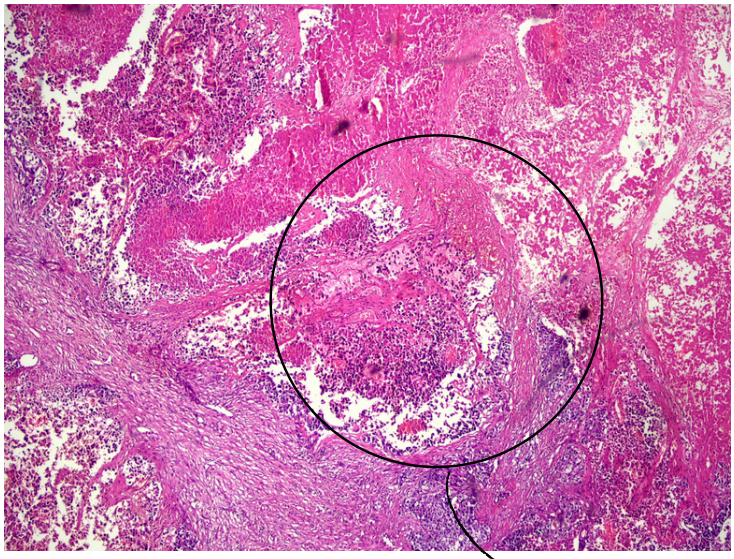

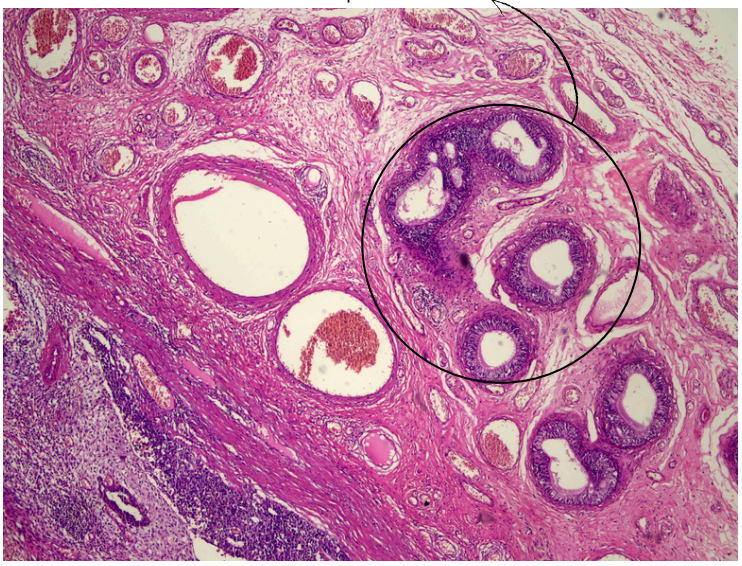

Células tumorais em meio a hemorragia e necrose

Microscopia óptica, Hematoxilina-eosina

Aumento 100x:

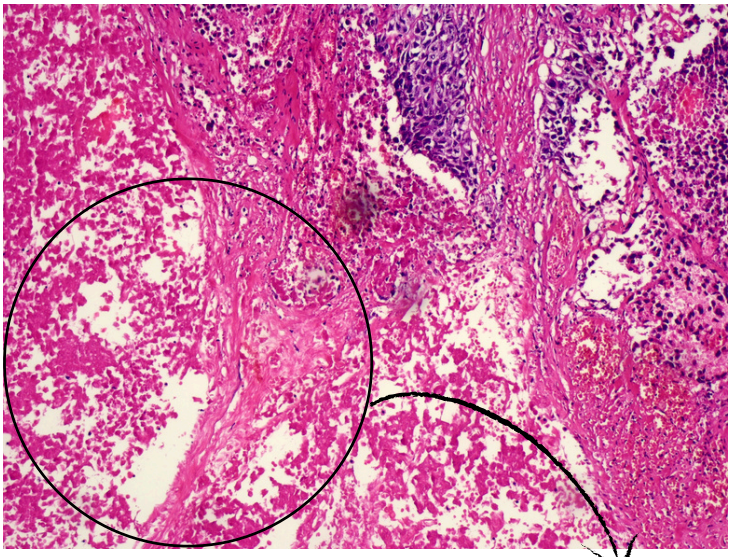

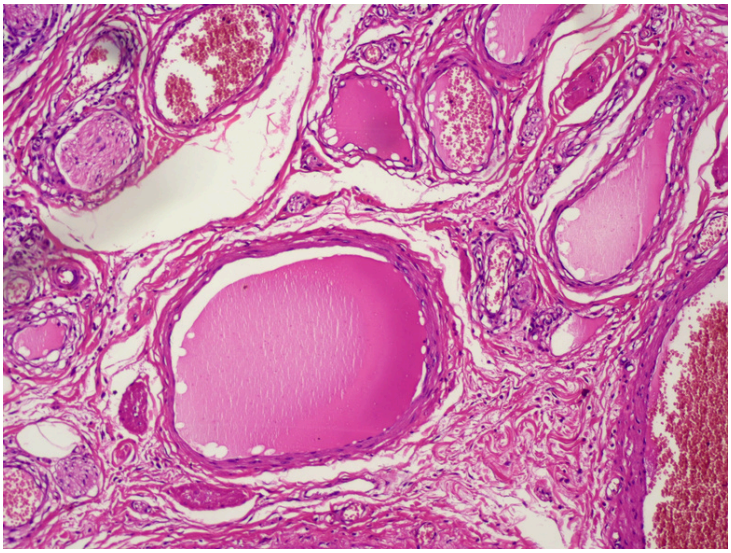

Aumento 400x:

Necrose intratumoral

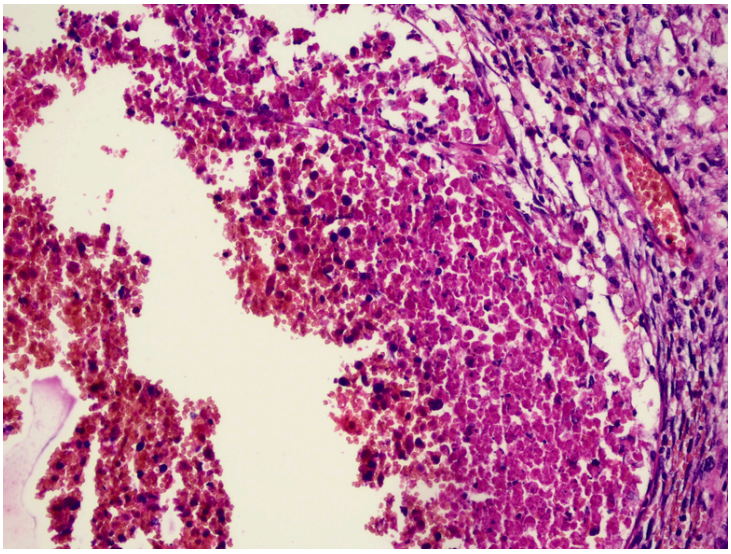

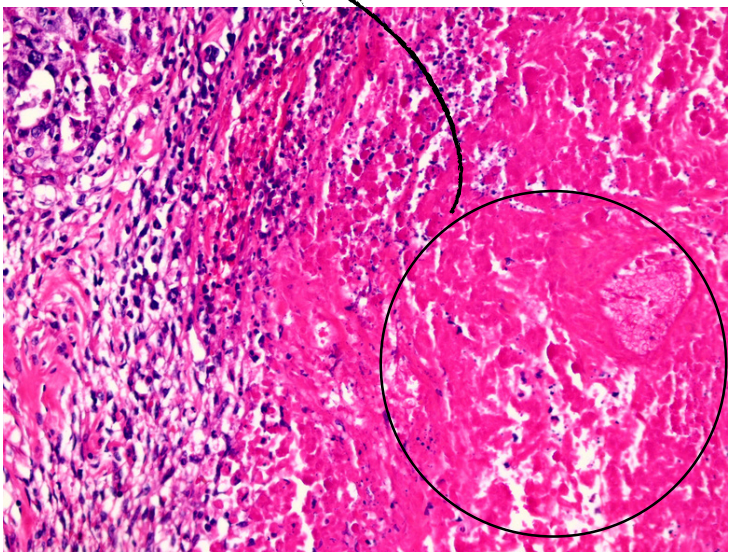

Epididimo livre de neoplasia

Hemorragia

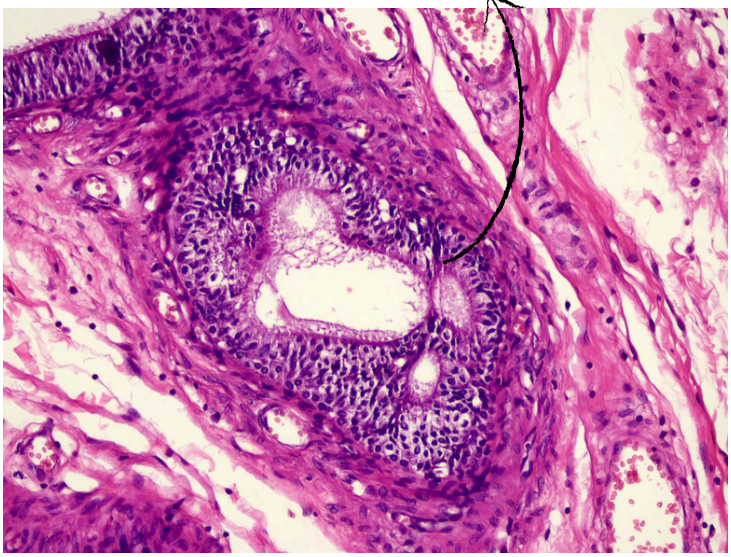

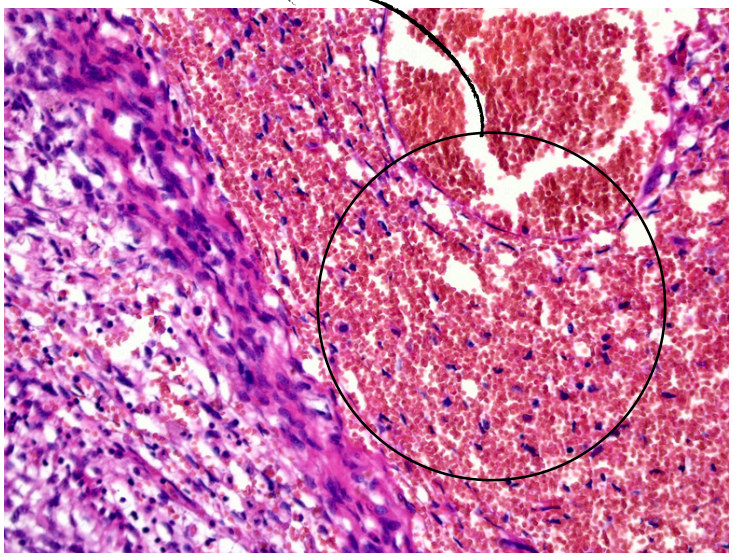

SAIBA MAIS...

O Carcinoma embrionários é o segundo principal tipo histológico de câncer de testículo, oriundo de células germinativas, sendo mais agressivo que o seminoma. O tumor é composto de proliferação de células em padrão sólido, por vezes de aspecto glandular com lúmen, contendo pleomorfismo celular acentuado e alto grau nuclear, podendo ocorrer invasão tecidual de estruturas adjacentes. É recomendável realizar imunoistoquímica (CD30 e Citoqueratinas) para a confirmação do diagnóstico e pesquisa de outros componentes germinativos associados.

M6- TERATOMA TESTICULAR COM TRÊS FOLHETOS

Aumento 40x:

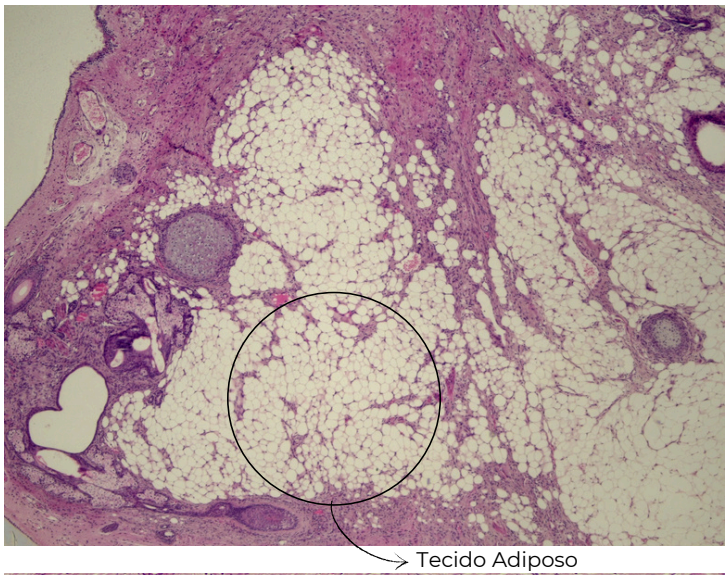

Tecido Adiposo

Cisto epidérmico

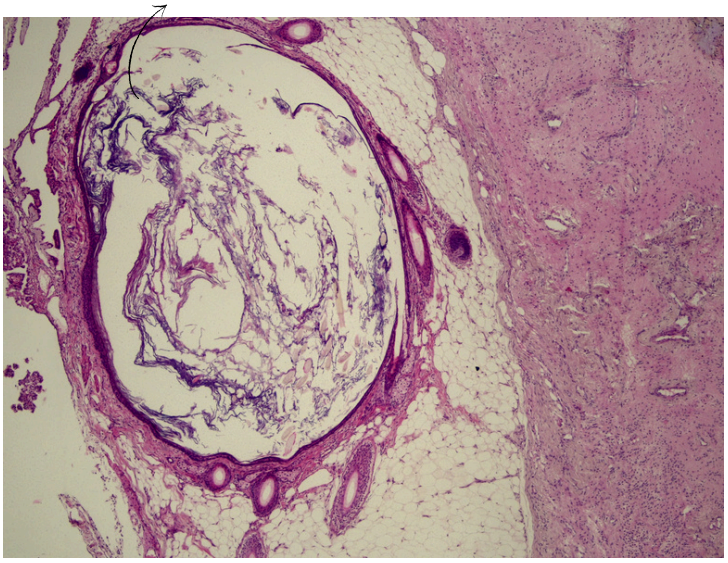

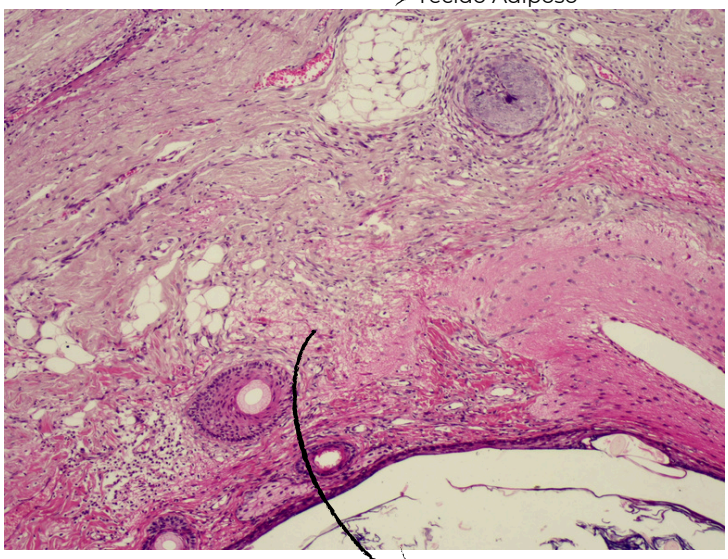

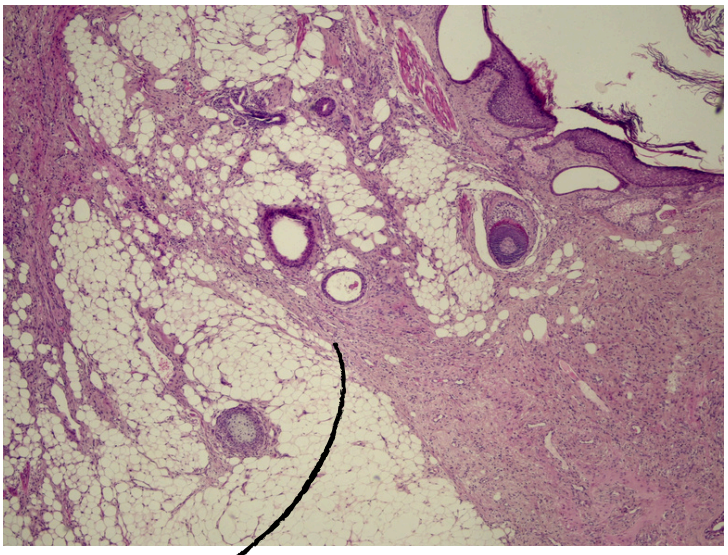

Diferentes tipos teciduais observáveis

Aumento 200x:

Glândulas sebáceas

Cartilagem

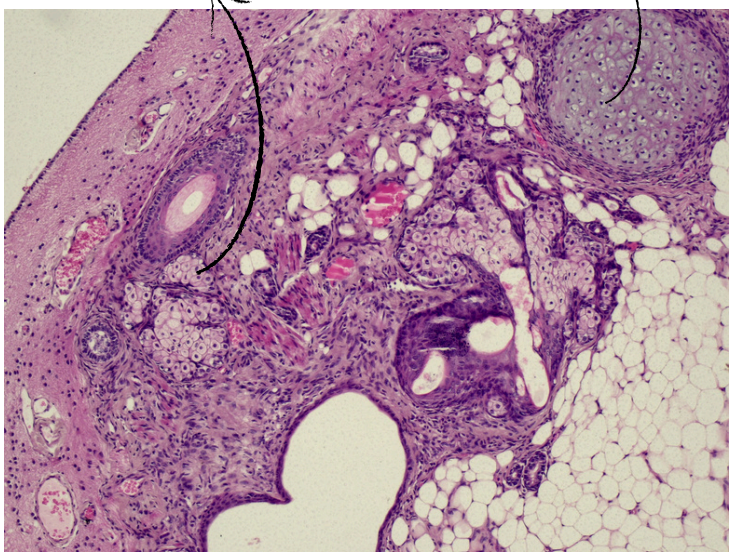

Cisto epidérmico

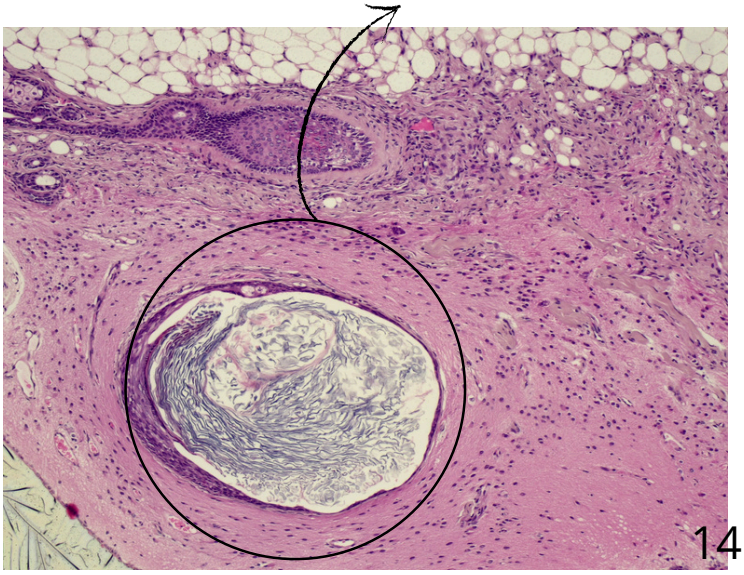

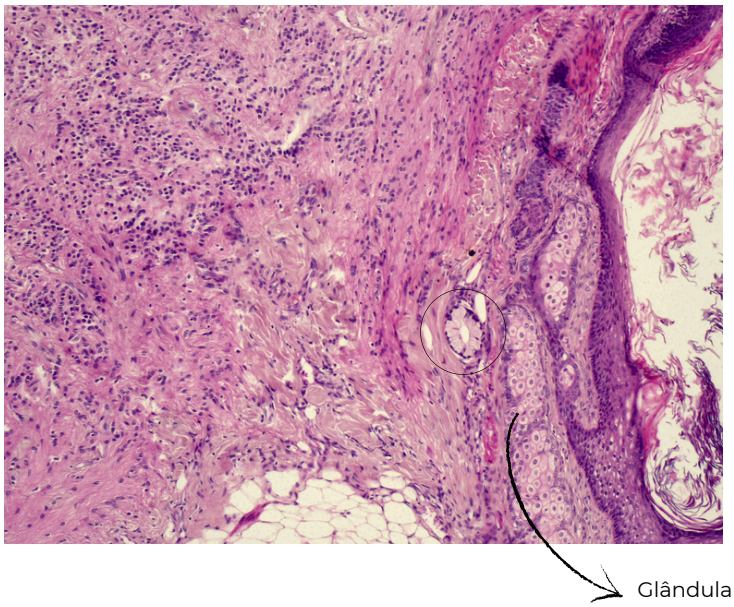

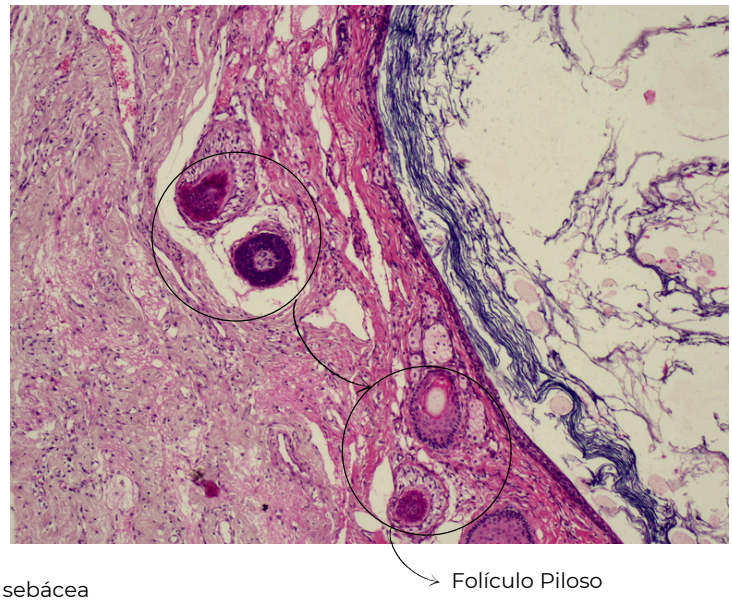

Aumento 400x:

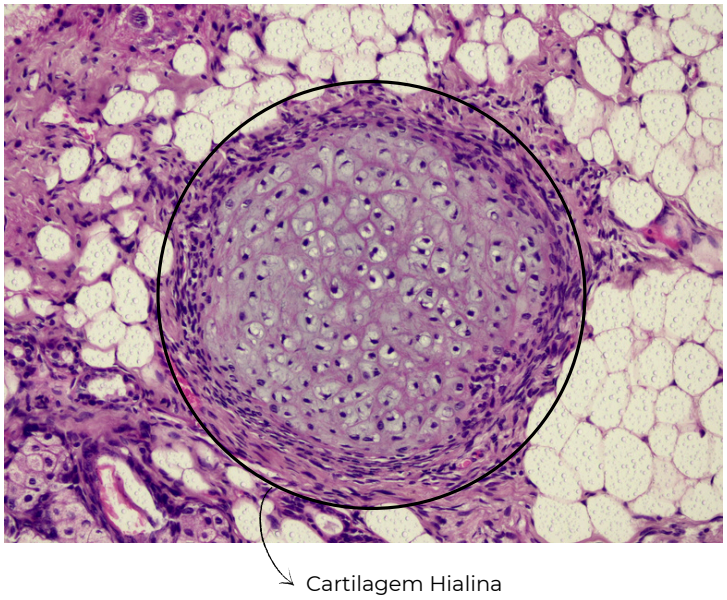

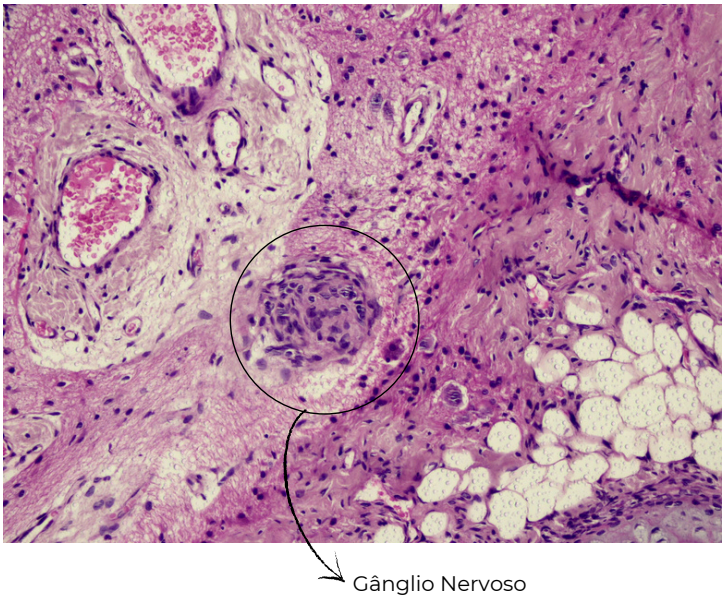

SAIBA MAIS...

O teratoma testicular é uma neoplasia de células germinativas contendo tecidos derivados dos três folhetos embrionários (ectoderme, mesoderme, endoderme). Na lâmina, há presença de tecido adiposo, nervoso, tegumentar e cartilaginoso. Microscopicamente, destaca-se cistos revestidos por epiderme contendo lamelas córneas na luz , folículos pilosos, cartilagem do tipo hialina e grande quantidade de adipócitos.

M4- GINECOMASTIA

Aumento 40x:

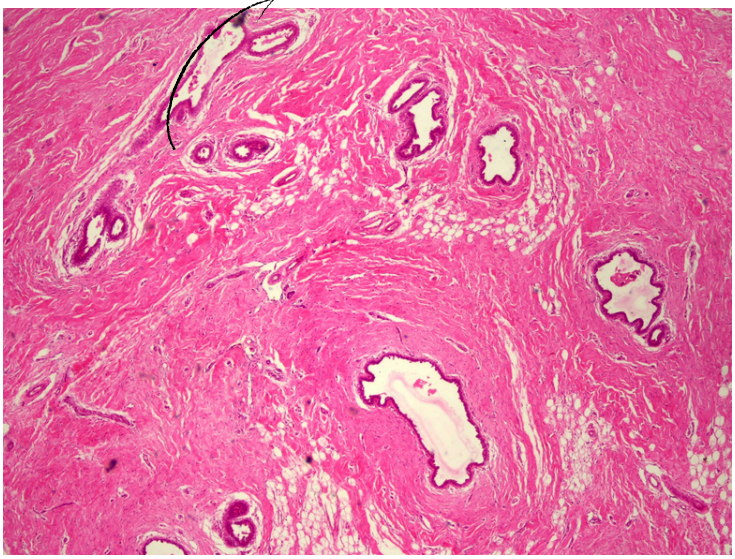

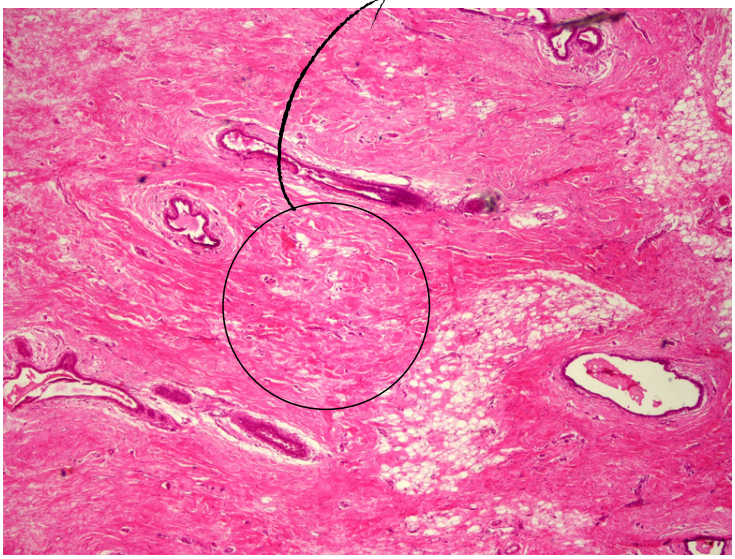

Aumento 200x:

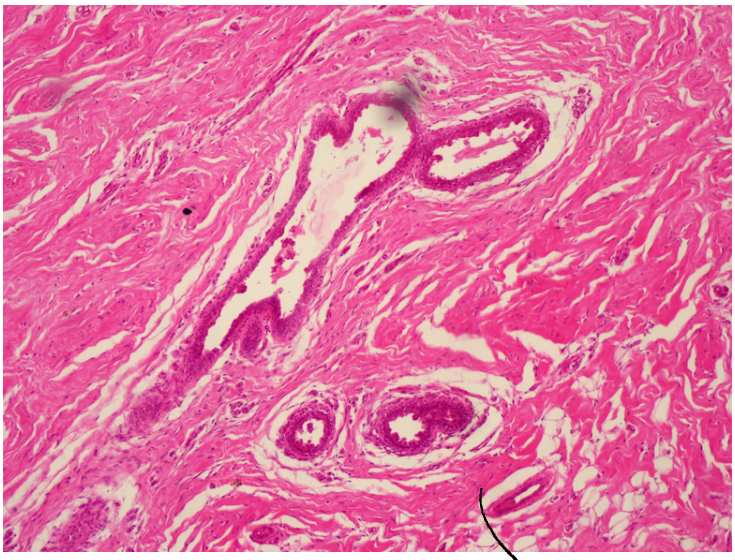

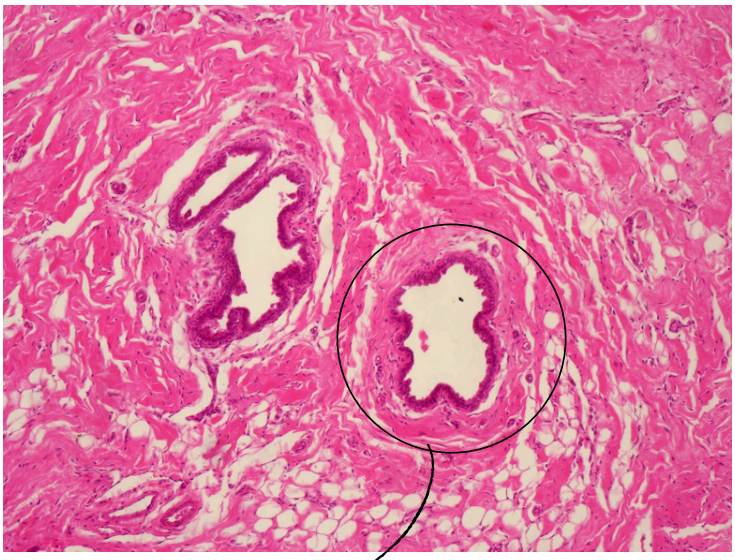

Glândulas hipertrofiadas

Aumento 400x:

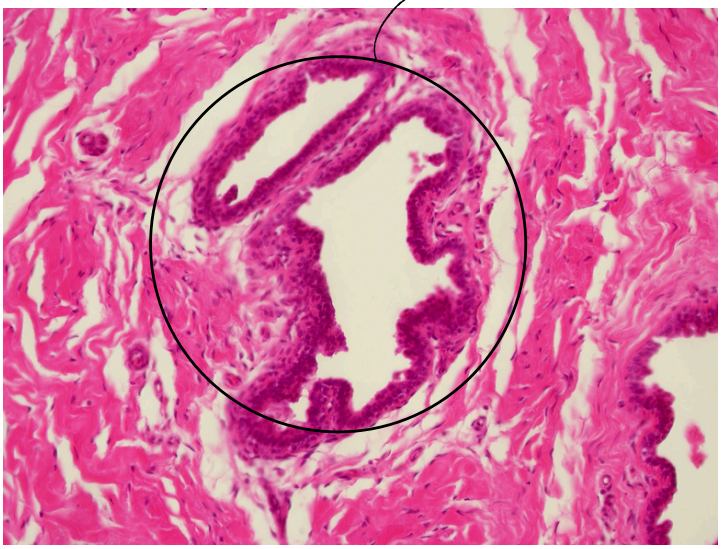

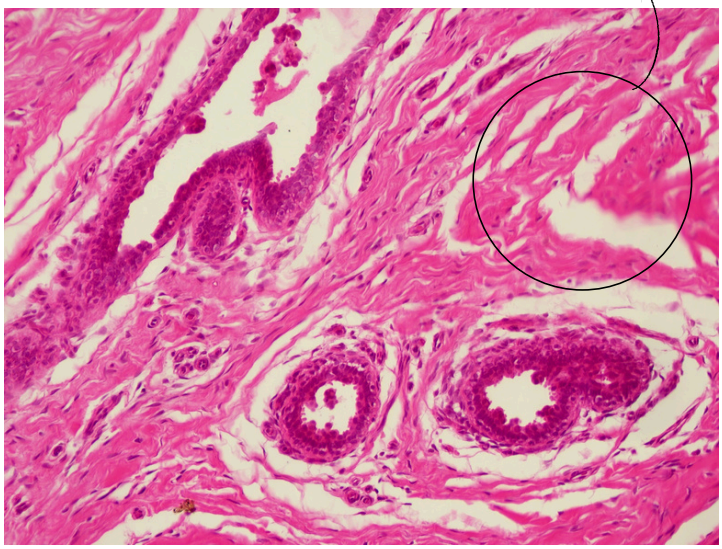

SAIBA MAIS...

Na ginecomastia (aumento benigno da mama masculino), observa-se proliferação de ductos mamários com trajetos irregulares e hiperplasia epitelial sem atipias. Há aumento de estroma conjuntivo frouxo, muitas vezes edemaciado, sem formação de lóbulos verdadeiros. Pode ocorrer infiltrado linfocitário discreto em casos mais crônicos.

DEPARTAMENTO DE PATOLOGIA MÉDICA

UFPR

Curitiba

2025